

King of Hearts Express® Recorder – Case Study

“I Get Very Lightheaded and I Almost Pass Out. I Did Faint Once.”

Situation:

A 76-year-old woman was referred for syncope.

History:

She had been experiencing near syncope for three or four weeks prior to her appointment. She had one witnessed syncopal episode with some seizure activity. Exercise testing showed transient AV block without symptoms. She was sent home with the King of Hearts Express® cardiac event recorder.

Outcome:

Two days later, the patient returned to the office with the King of Hearts Express recorder after experiencing three near-syncopal episodes. The event recorder was played back in the office. The ECG showed some 2:1 AV block followed by a period of complete heart block with a 4.5-second period of asystole. She was admitted to the hospital that afternoon and the next day a dual-chamber pacemaker was implanted. She has had no recurrence of her symptoms.

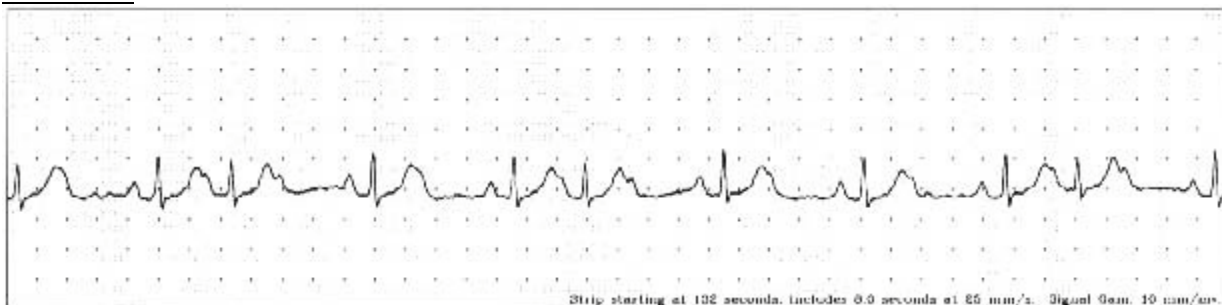
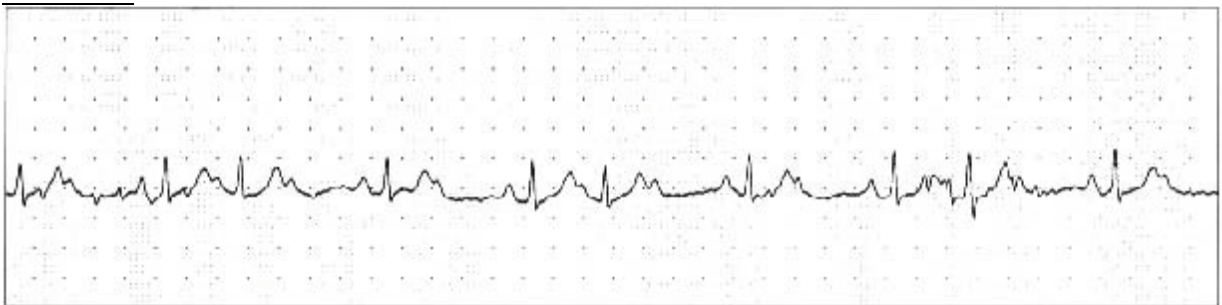
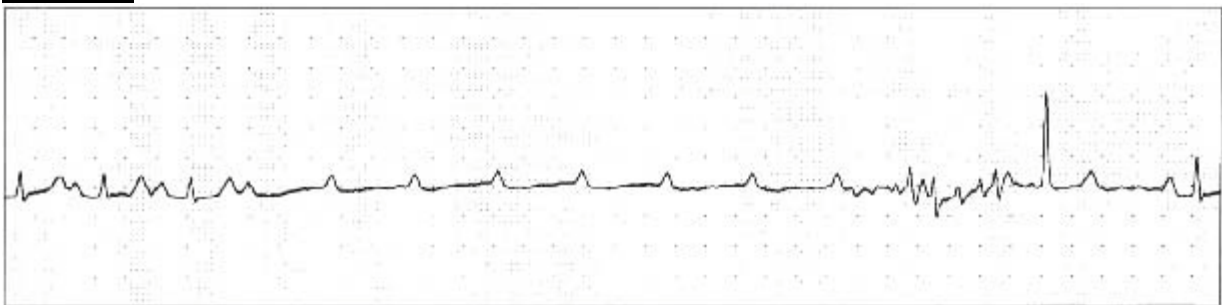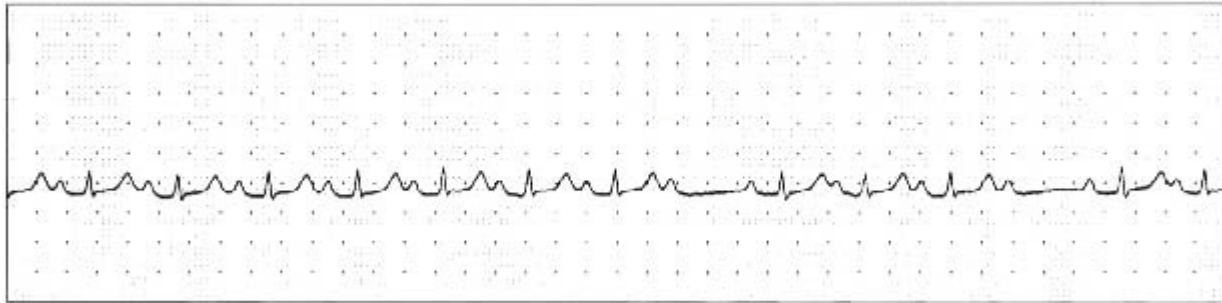
Once again the usefulness of long-term cardiac event recording was affirmed.

Equipment:

The King of Hearts Express Cardiac Event Recorder.

*From case files of Cardiovascular Consultants of Maine, Portland, ME
Courtesy of: Cheryl S. DeGrandpre, MS and John C. Love, MD*

King of Hearts Express® Recorder – Case Study



Instromedix®

A Card Guard® Company

6779 Mesa Ridge Road, Suite 200 • San Diego, CA 92121

Phone: 800-633-3361 • Fax: 858-777-2373 • www.instromedix.com