

# King of Hearts Express® Recorder – Case Study

## “The Paramedics Saved My Life.”

### **Situation:**

A cardiac event recorder was prescribed to evaluate unexplained syncope in an 83-year-old man.

### **History:**

The patient had a history of coronary artery disease treated by three-vessel coronary artery bypass grafting, congestive heart failure, chronic renal insufficiency, carotid stenosis and peripheral vascular disease. A King of Hearts Express® cardiac event recorder was ordered.

### **Outcome:**

The patient transmitted several event recordings with complaints of "chest discomfort and suffocating feeling." These recordings were associated with sinus rhythm at 75-86 beats per minute with isolated atrial and ventricular premature complexes. On the eleventh day of monitoring, the patient experienced a "terrible spell" with near-syncope, and activated his event recorder.

He did not lose consciousness. He transmitted three sequential events showing wide-complex tachycardia consistent with sustained ventricular tachycardia lasting more than three minutes.

Emergency Medical Services were dispatched. The patient was hypotensive. Sinus rhythm was restored after a 100-joule shock. The patient was transferred to a coronary care unit.

After electrophysiology study and RF ablation, a permanent DDDR pacemaker was implanted. The patient was discharged to a recuperative center for rehabilitation.

Once again the usefulness of long-term cardiac event recording was affirmed.

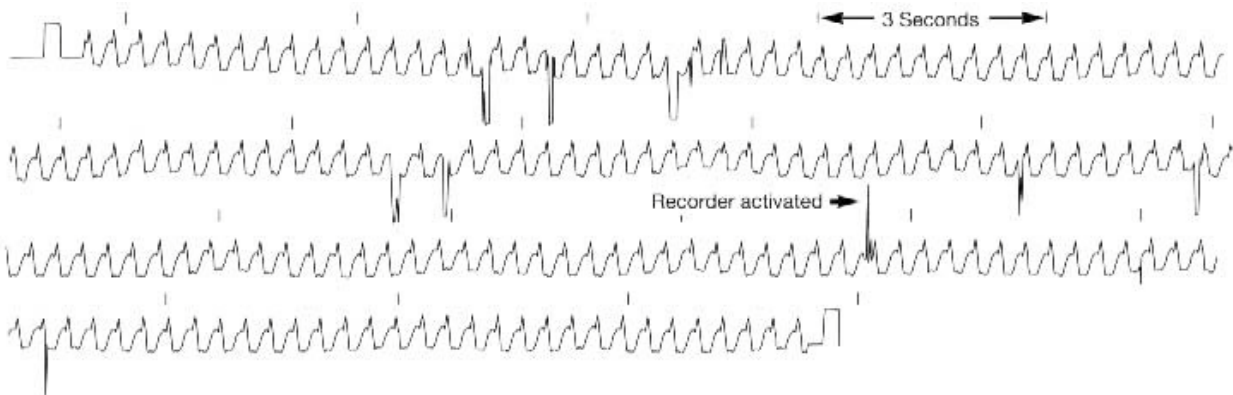
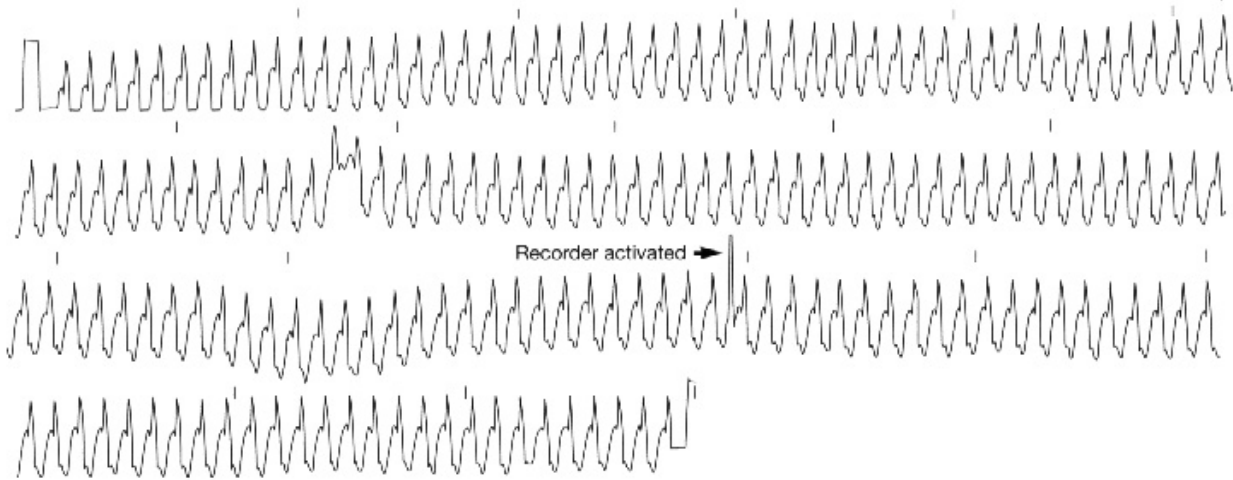
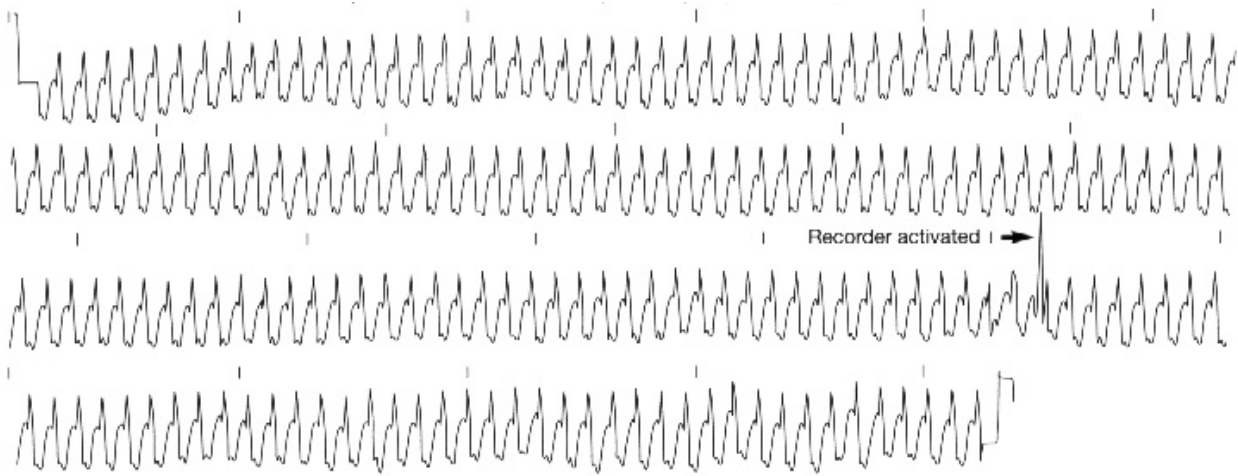
### **Equipment:**

The King of Hearts Express Cardiac Event Recorder.

*From case files of Beth Israel Hospital, Boston, MA*

*Courtesy of: Ary L. Goldberger, MD, Mark E. Josephson, MD, and Diane Perry, CCT*

# King of Hearts Express® Recorder – Case Study



**Instromedix®**

A Card Guard® Company

6779 Mesa Ridge Road, Suite 200 • San Diego, CA 92121

Phone: 800-633-3361 • Fax: 858-777-2373 • [www.instromedix.com](http://www.instromedix.com)