

King of Hearts Express® Recorder – Case Study

“I Get Lightheaded and Feel This Pressure In My Chest.”

Situation:

A 33-year-old man complained of occasional palpitations resulting in lightheadedness and chest pressure.

History:

Resting ECG and echocardiography were normal. Exercise stress test revealed no provokable ST changes or arrhythmia. Holter monitoring did not reveal any arrhythmias correlated with symptoms. The King of Hearts Express® cardiac event recorder was ordered.

Outcome:

The patient sent three transmissions, each containing four symptom-correlated events. Each recording showed normal sinus rhythm with a short PR interval (<120 MS). There were brief episodes of junctional rhythm at a rate of 40 beats per minute.

The patient was referred for electrophysiology study. The diagnosis was Wolf-Parkinson-White syndrome.

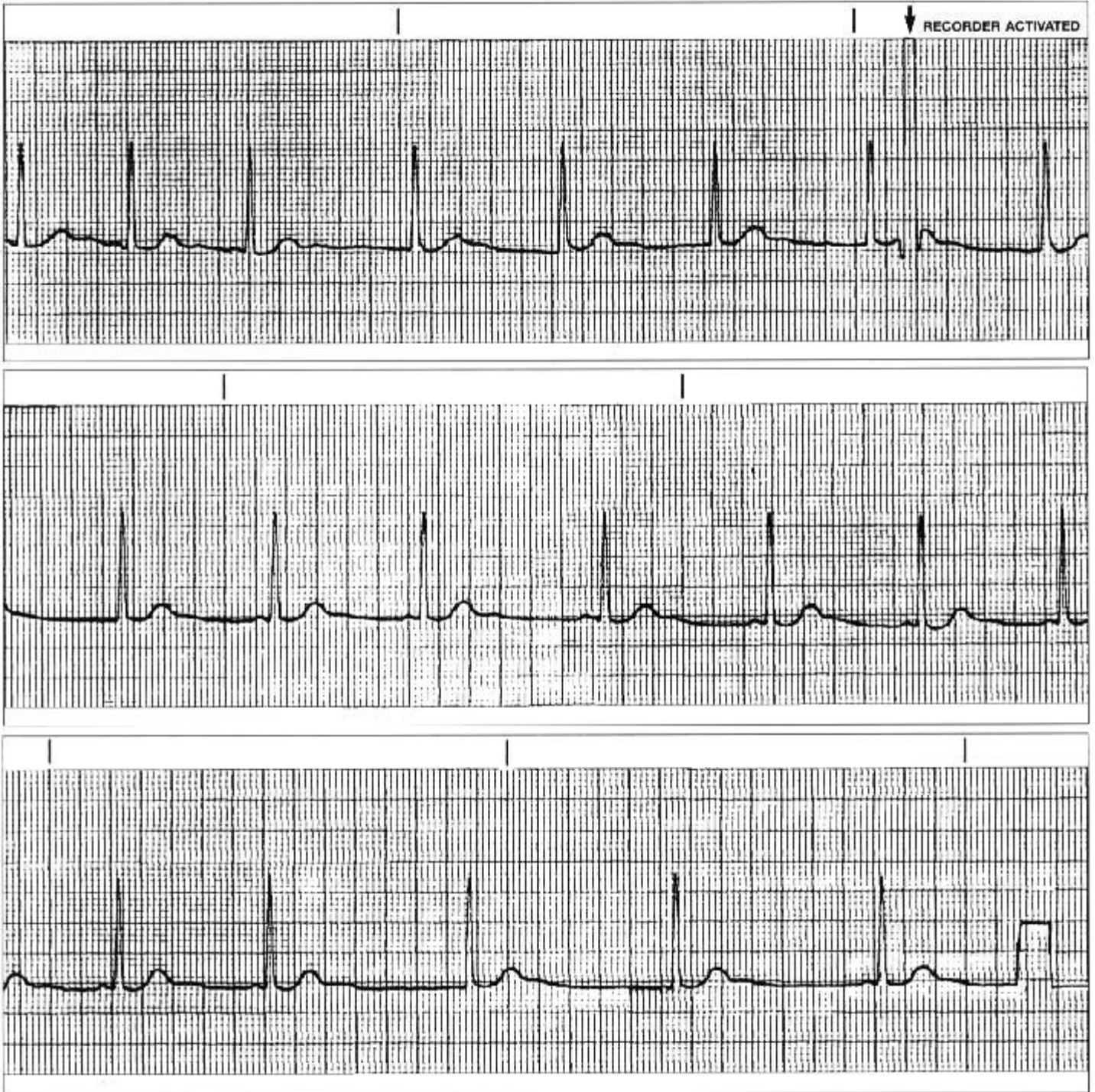
Once again the usefulness of long-term cardiac event recording was affirmed.

Equipment:

The King of Hearts Express Cardiac Event Recorder.

*From case files of Melrose-Wakefield Hospital, Melrose, MA
Courtesy of: Margaret A. Gephard and Bruce Watrous, MD*

King of Hearts Express® Recorder – Case Study



Instromedix®

A Card Guard® Company

6779 Mesa Ridge Road, Suite 200 • San Diego, CA 92121

Phone: 800-633-3361 • Fax: 858-777-2373 • www.instromedix.com